

## Coherence Between Cortical and Muscular Activities After Subcortical Stroke

Tatsuya Mima, Keiichiro Toma, Benjamin Koshy and Mark Hallett

*Stroke*. 2001;32:2597-2601

doi: 10.1161/hs1101.098764

*Stroke* is published by the American Heart Association, 7272 Greenville Avenue, Dallas, TX 75231

Copyright © 2001 American Heart Association, Inc. All rights reserved.

Print ISSN: 0039-2499. Online ISSN: 1524-4628

The online version of this article, along with updated information and services, is located on the World Wide Web at:

<http://stroke.ahajournals.org/content/32/11/2597>

**Permissions:** Requests for permissions to reproduce figures, tables, or portions of articles originally published in *Stroke* can be obtained via RightsLink, a service of the Copyright Clearance Center, not the Editorial Office. Once the online version of the published article for which permission is being requested is located, click Request Permissions in the middle column of the Web page under Services. Further information about this process is available in the [Permissions and Rights Question and Answer](#) document.

**Reprints:** Information about reprints can be found online at:  
<http://www.lww.com/reprints>

**Subscriptions:** Information about subscribing to *Stroke* is online at:  
<http://stroke.ahajournals.org/subscriptions/>

# Coherence Between Cortical and Muscular Activities After Subcortical Stroke

Tatsuya Mima, MD; Keiichiro Toma, MD; Benjamin Koshy, BS; Mark Hallett, MD

**Background and Purpose**—Functional connection between the motor cortex and muscle can be measured by electroencephalogram-electromyogram (EEG-EMG) coherence. To evaluate the functional connection to muscle between contralateral and ipsilateral motor cortices after pyramidal tract lesions, we investigated 6 patients with chronic subcortical stroke.

**Methods**—High-resolution EEG and EMG of the hand, forearm, and biceps muscles were recorded during 3 tonic contraction tasks: (1) elbow flexion, (2) wrist extension, and (3) power grip. To evaluate the cortical control of EMG, EEG-EMG coherence was computed.

**Results**—EEG-EMG coherence was localized over the contralateral sensorimotor area in all circumstances, and there was no significant coherence at the ipsilateral side. EEG-EMG coherence was significantly smaller on the affected side for the hand and forearm muscles but not for the biceps muscle.

**Conclusions**—All direct functional connections to muscle after recovered subcortical stroke come from the contralateral motor cortex. The different effects of the lesion on the proximal and distal muscles appear to be associated with the strength of the corticospinal pathway. (*Stroke*. 2001;32:2597-2601.)

**Key Words:** electroencephalogram ■ electromyogram ■ motor cortex

Improved motor function can be observed in patients with stroke. Previous human studies using PET, functional MRI, transcranial magnetic stimulation, or EEG suggested the possible recruitment of the ipsilateral motor cortex or other secondary motor areas as potential mechanisms of recovery in patients with prior strokes.<sup>1-7</sup> The exact role of the ipsilateral motor cortex in controlling the muscle activity, however, is not yet fully understood. In this study, we investigated the corticomuscular coherence in patients with subcortical pyramidal tract lesions to clarify the changes in corticomuscular connection that might occur after brain injury associated with stroke.

During a tonic muscle contraction, functional coupling between the cortex and muscle can be measured by the coherence between cortical oscillatory activity and electromyogram (EMG).<sup>8-11</sup> This coherence is spatially localized over the contralateral primary sensorimotor area and is observed mainly within the frequency range of 14 to 50 Hz. In a previous study using the human EEG,<sup>12</sup> we showed that the EEG leads the EMG with a constant short time lag that depended on the corticomuscular distance, suggesting that EEG-EMG coherence is associated with the cortical control of the grouped motor unit firing predominantly through the direct corticospinal pathway. Analysis of this EEG-EMG coherence can provide a useful tool for understanding the corticomuscular functional connection in

stroke recovery. In the present study, we selected only long-term patients with good recovery to evaluate the EEG-EMG coherence during the same task for the affected and unaffected sides.

## Subjects and Methods

### Patients

Six patients (mean age 63 years, range 53 to 72 years, 1 woman, 5 men) with chronic right hemiparesis were involved in the present study. All patients were right-handed as assessed with the Edinburgh questionnaire (mean laterality quotient 0.88 [0.6 to 1]).<sup>13</sup> All patients suffered from a pure motor paresis after a left subcortical infarction with no somatosensory symptoms clinically. There was no history of prior stroke with sensory or motor deficits. The mean time after stroke onset was 4.3 years (range 1 to 9 years). All patients suffered from a severe hemiparesis (no or minimal movement, no antigravity effort) at the acute stage. At the time of the experiment, the patients had recovered well and showed only mild hemiparesis (mild drift during the arm extension and disturbance of the fine finger movements), except for patient 2, who had difficulty in maintaining wrist extension. MR images of the brain showed small lacunar infarctions in the left pons (patient 6), globus pallidus (patients 1 and 3), internal capsule (patients 1, 2, 3, 4, and 5), or corona radiata (patients 2 and 4). Three patients had a small additional infarction in the left cerebellum (patient 2), right thalamus (patient 1), and right putamen (patient 3). Patients did not take any special medications, such as antiepileptic drugs or tranquilizers. The protocol was approved by the Institutional Review Board, and patients gave their written informed consent for the experiments.

Received April 27, 2001; final revision received August 1, 2001; accepted August 21, 2001.

From the Human Motor Control Section, Medical Neurology Branch, National Institute of Neurological Disorders and Stroke, National Institutes of Health, Bethesda, Md.

Reprint requests to Mark Hallett, MD, NIH, NINDS, Medical Neurology Branch, Building 10, Room 5N226, 10 Center Dr, MSC1428, Bethesda, MD 20892-1428. E-mail hallettm@ninds.nih.gov

© 2001 American Heart Association, Inc.

Stroke is available at <http://www.strokeaha.org>

## Methods

To assess the cortical control of EMG activity, EEG-EMG coherence was computed during weak tonic contraction tasks: (1) elbow flexion (biceps muscle contraction), (2) wrist extension (extensor carpi radialis [ECR] muscle contraction), and (3) power grip using all digits. For the elbow flexion and wrist extension tasks, subjects were instructed to keep a light static contraction by performing the tasks against gravity. To make wrist extension of the affected (right) side easier, patients held a soft sponge ball in their task-performing hand. Therefore, the wrist extension task in the present study was partly realized by a cocontraction of wrist extensor and flexor muscles. To achieve intrinsic hand muscle contraction, the power grip task was applied because it was easy to perform with the affected hand. For the power grip task, the maximal grip power was measured with a force transducer. Then subjects were instructed to keep the constant force level at 10% to 20% of the maximum force with the aid of the visual feedback from the force transducer. Patients were instructed to avoid mirror movements during tasks, and the EMG at the contralateral side was monitored.

## Recording and Analysis

The sequential order of tasks was randomized among patients. The EEG and EMG signals were recorded for a total of  $\approx 5$  minutes, with 1 or 2 short breaks during the session to avoid fatigue. The EEG signals were recorded with a linked-earlobe reference from 56 electrodes mounted on a cap (Electro-cap International Co), which were arrayed according to the extended international 10-20 system. Surface EMG was recorded from the right and left biceps muscle during the elbow flexion task, the right and left ECR and flexor carpi radialis muscles during the wrist extension task, and the right and left opponens pollicis (OP) and first dorsal interosseous (FDI) muscles during the power grip task. EMG signals were rectified to extract the timing information of muscle action potentials.<sup>14</sup>

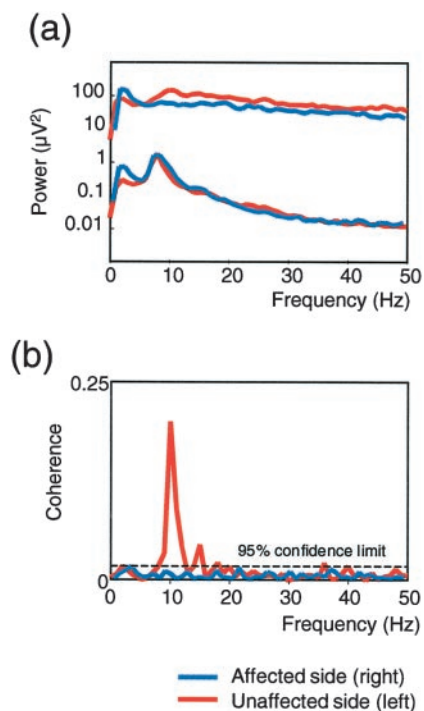
EEG and EMG signals were filtered at a bandpass of 1 to 200 Hz and digitally converted at a sampling rate of 1000 Hz (Neuroscan, Neuroscan Inc). Electrode impedance was kept below 5 k $\Omega$ . To increase the spatial resolution of EEG signals, the current source density function of the EEG signal was computed by use of the dipole derivation utility of the Neuroscan software. Details of the parameters for this computation have been reported previously.<sup>10,12</sup> Surface EMG was used to record the aggregate muscle action potentials.<sup>15</sup> The EMG over OP could be contaminated by other thenar muscle activity. This lack of selectivity should have little impact, however, on the comparison between muscle groups (proximal versus distal).

EEG and EMG signals were segmented into artifact-free epochs of 1024 ms in duration without overlapping (mean 172 epochs, range 150 to 200 epochs). To measure the linear correlation between EEG and EMG, coherence was calculated with a fast Fourier transform algorithm with a frequency resolution of 0.98 Hz, according to the following equation:

$$|R_{xy}(i)|^2 = \frac{|f_{xy}(i)|^2}{f_{xx}(i) \times f_{yy}(i)}$$

In this equation,  $f_{xx}(i)$  and  $f_{yy}(i)$  are autospectra of the EEG and EMG signals,  $x$  and  $y$ , for a given frequency ( $i$ ), and the  $f_{xy}(i)$  is the cross-spectrum between them. Coherence is expressed as a real number between 0 and 1, with 1 indicating a perfect linear association. EEG-EMG coherence was considered significant when it was  $>95\%$  confidence limits computed from the number of epochs (epochs 150 to 200; limit 0.020 to 0.015). The EEG electrode having the highest EEG-EMG coherence was selected for further analysis.

Coherence was normalized by use of the arc hyperbolic tangent transformation and statistically compared by ANOVA.<sup>14</sup> The frequency range of 3 to 50 Hz, covering most of the scalp-recorded EEG power spectra, was the subject of further analysis. In addition to the peak coherence value, the number of frequency bins that showed significant coherence was also statistically compared.



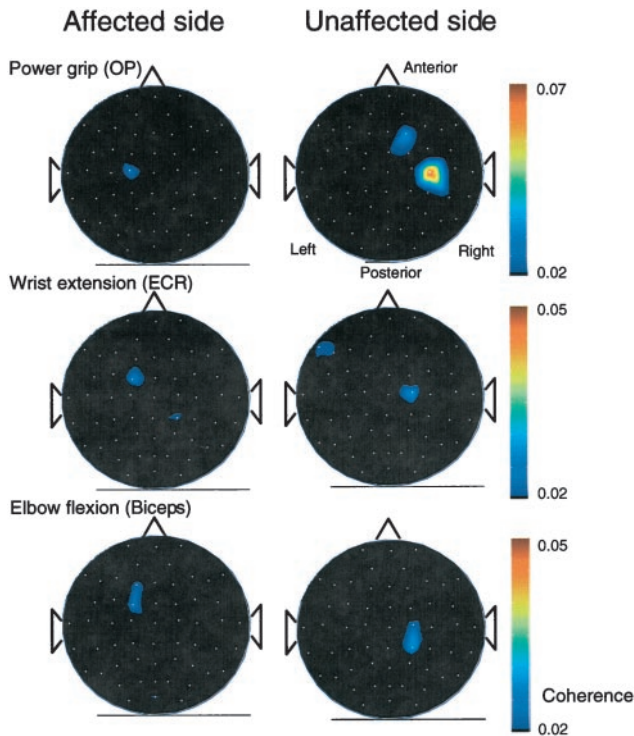
**Figure 1.** a, The EEG (C3) and EMG (OP muscle) power spectra at the affected (blue line) and unaffected (red line) sides in patient 2 during the power grip task ( $n=170$  and  $182$ , respectively). EMG power at the affected side is slightly smaller than that at the unaffected side. The general spectral pattern is similar, however, for both sides. b, The EEG-EMG coherence spectra at the affected (blue line) and unaffected side (red line) in the same patient. The gray horizontal line indicates the 95% confidence limit. Significant EEG-EMG coherence is observed only at the unaffected side (peak 11 Hz).

## Results

The mean maximal forces produced by the power grip task were  $13.5 \pm 8.6$  and  $17.3 \pm 5.9$  (mean  $\pm$  SD) kg for the affected (right) and unaffected (left) sides, which were significantly different ( $P < 0.05$ ).

A typical example of EEG and EMG power spectra and EEG-EMG coherence spectra for 1 patient is shown in Figure 1. The topographic distribution of EEG-EMG coherence showed the highest significant coherence between EEG and EMG over the frontocentral area contralateral to the task side (either FC3/4, FC1/2, C3/4, C1/2, CP3/4, or CP1/2, depending on the patients and tasks, Figure 2). There was no significant stable EEG-EMG coherence over the ipsilateral frontocentral area. Cortical representation of biceps, ECR, and OP muscles largely overlap with each other, and the peak locations are not significantly different ( $P=0.843$ ).

For the peak coherence (Table), the main effect of side and the interaction between side and task were significant ( $P < 0.01$  and  $P < 0.05$ , respectively). For the number of bins, the main effects of side and task were significant ( $P < 0.001$ ,  $P < 0.001$ , respectively), and their interaction was also significant ( $P < 0.001$ ). For the peak frequency, the main effects of task and side were not significant ( $P=0.519$  and  $P=0.578$ , respectively). Therefore, the



**Figure 2.** Scalp topography of the EEG-EMG coherence in patient 4. The frequency with the peak coherence is selected for each task to show the distribution. Coherence value below the 95% confidence limit (0.02) is set to black for the construction of the map. EEG-EMG coherence is localized over the contralateral sensorimotor area and was larger at the unaffected side. In this patient, there is a tendency that the coherence at the affected side is more anteriorly and medially located than that at the unaffected side.

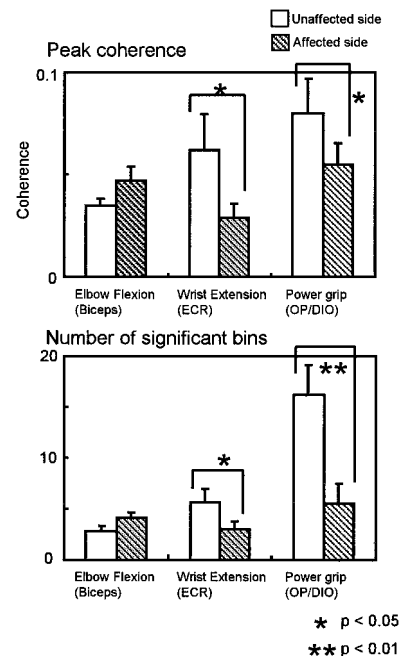
effect of side on peak coherence and that of the number of bins were separately assessed for 3 tasks (Figure 3, Table). For the elbow flexion task, the effect of side on coherence and number of bins was not significant ( $P=0.127$ ,  $P=0.191$ , respectively). For the wrist extension and power grip tasks, the effect of side was significant (coherence  $P<0.05$  and  $P<0.05$ , number of bins  $P<0.05$  and  $P<0.001$ , respectively).

The results of the coherence analysis in patients 1 and 3, who were found to have additional lesions in the right hemisphere (no clinical symptoms), were similar to those in the other patients.

### Discussion

The results of the present study show changes in EEG-EMG coherence after the alterations of the central motor pathway due to stroke. We selected patients with subcortical lacunar stroke because the morphological structure of the sensorimotor cortex is mostly preserved in these patients.

We found a significant reduction in EEG-EMG coherence for the OP and ECR muscles on the affected side, suggesting that the central motor pathway is necessary for the generation of EEG-EMG coherence during tonic contraction. This coherence difference cannot be attributed to



**Figure 3.** Top, Comparison of the peak EEG-EMG coherence between the affected and unaffected sides for 3 tasks. Normalized (arc hyperbolic tangent transformed) coherence is shown (mean±SEM). For the wrist extension and power grip tasks, coherence for the affected side is significantly smaller than that for the unaffected side. Bottom, Comparison of the number of frequency bins that showed the significant EEG-EMG coherence between the affected and unaffected sides for 3 tasks (mean±SEM). For the wrist extension and power grip tasks, coherence for the affected side is significantly smaller than that for the unaffected side.

the difference in the produced force, because EEG-EMG coherence is not affected by the magnitude of force at the mild to moderate level.<sup>16</sup> Because the patients suffered from a pure motor paresis without sensory symptoms, it is highly likely that EEG-EMG coherence conveys the central motor command but not the sensory afferent feedback. This result is predictable, given the positive time delay from the cortex to the muscle in normal volunteers.<sup>11,12,17,18</sup> The finding also agrees with the previous study,<sup>12</sup> which

### EEG-EMG Coherence

	Task		
	Elbow Flexion (Biceps)	Wrist Extension (ECR)	Power Grip (OP)
Frequency (Hz)			
Unaffected	25±3	28±7	24±5
Affected	29±5	30±7	29±4
Coherence			
Unaffected	0.035±0.003	0.062±0.017	0.080±0.017
Affected	0.047±0.007	0.029±0.007	0.055±0.010
Number of bins			
Unaffected	3±1	6±1	16±3
Affected	3±1	3±1	6±2

Values are mean±SEM.

showed the absence of an interference effect of somatosensory stimuli on EEG-EMG coherence.

Large-scale brain plasticity, such as emergence or enhancement of the ipsilateral corticospinal connection, has been reported to occur in hemispheric lesions in early childhood.<sup>3</sup> In the present study, however, there was no evidence favoring the enhancement of the ipsilateral pathway to the muscle in terms of EEG-EMG coherence. The topographic distribution of significant EEG-EMG coherence on the affected side was essentially the mirror image of that on the unaffected side, with a smaller coherence estimate. This divergence might be partly explained by the difference in patient population, because only adult patients with mean poststroke duration of 4.3 years were involved in the present study. The functional role of the ipsilateral corticomotoneuronal connection is still controversial, because previous studies using transcranial magnetic stimulation reported that the ipsilateral EMG responses from the unaffected hemisphere did not correlate with clinical recovery.<sup>19–21</sup> If the ipsilateral connection comes into play only when the contralateral connection fails, it is reasonable that those patients with good recovery recruited in the present study showed little or no ipsilateral EEG-EMG coherence. It is possible, however, that the ipsilateral (unaffected) sensorimotor cortex aids in motor control of the affected side through corticocortical connections or polysynaptic pathway,<sup>4,22</sup> which might not make a large contribution to the generation of EEG-EMG coherence because of jittering.

Another possible recovery mechanism may involve the nonprimary motor cortical areas.<sup>21</sup> In the present study, some patients showed a tendency that the EEG-EMG coherence peak for the affected side was more anteriorly and/or medially located than that for the unaffected side, as shown in Figure 2. This finding might indicate the possible contribution of lateral and/or medial premotor area muscle control, which has been suggested by PET studies.<sup>23–25</sup> Recent electrocorticographic study showed the contribution of the medial premotor area for the generation of this coherence.<sup>26</sup> Differentiation of primary motor and premotor activity might be difficult, however, because of the limited spatial resolution of the EEG technique. The clear significant reduction of coherence on the affected side suggests that this compensation associated with the nonprimary motor areas, if any, does not contribute that much to generation of EEG-EMG coherence.

Clinically, it is well known that the distal hand muscles are more severely affected than the proximal muscles in patients with lacunar stroke. This pattern is also true for recovery from acute stroke; the motor functions of the shoulder and elbow return first. The exact underlying mechanism is not known but is probably associated with the strength of the descending direct corticospinal pathway.<sup>19,27</sup> This clinical recovery pattern agrees with the electrophysiological finding that EEG-EMG coherence on the affected side is smaller than that on the unaffected side for OP and ECR muscles but not for the biceps muscle. Because the present study was performed on chronic stroke patients, however, it is not clear whether this apparently

normal EEG-EMG coherence at the proximal muscle was caused by cortical reorganization or whether the preserved corticospinal tract for the biceps muscle caused the normal EEG-EMG coherence and the good recovery. The present results based on 6 stroke patients might be considered preliminary, and further studies will be needed for us to fully understand the recovery mechanism.

### Acknowledgments

Dr Mima was partly supported by Grant-in-Aid for Encouragement of Young Scientists 13780634 from the Japan Society for the Promotion of Science. The authors thank Drs Hiroshi Shibasaki and Takashi Nagamine for helpful comments and discussions, S. Thomas-Vorbach and Elaine Considine for expert technical assistance, and Devera G. Schoenberg, MSc, for skillful editing.

### References

- Nelles G, Spiekermann G, Jueptner M, Leonhardt G, Müller S, Gerhard H, Diener C. Reorganization of sensory and motor systems in hemiplegic stroke patients: a positron emission tomography study. *Stroke*. 1999;30:1510–1516.
- Cramer SC, Nelles G, Benson RR, Kaplan JD, Parker RA, Kwong KK, Kennedy DN, Finklestein SP, Rosen BR. A functional MRI study of subjects recovered from hemiparetic stroke. *Stroke*. 1997;28:2518–2527.
- Chollet F, DiPiero V, Wise RJS, Brooks DJ, Dolan RJ, Frackowiak RSJ. The functional anatomy of motor recovery after stroke in humans: a study with positron emission tomography. *Ann Neurol*. 1991;29:63–71.
- Benecke R, Meyer B-U, Freund HJ. Reorganization of descending motor pathways in patients after hemispherectomy and severe hemispheric lesions demonstrated by magnetic brain stimulation. *Exp Brain Res*. 1991;83:419–426.
- Farmer SF, Harrison LM, Ingram DA, Stephens JA. Plasticity of central motor pathways in children with hemiplegic cerebral palsy. *Neurology*. 1991;41:1505–1510.
- Honda M, Nagamine T, Fukuyama H, Yonekura Y, Kimura J, Shibasaki H. Movement-related cortical potentials and regional cerebral blood flow changes in patients with stroke after motor recovery. *J Neurol Sci*. 1997;146:117–126.
- Caramia MD, Lani C, Bernardi G. Cerebral plasticity after stroke as revealed by ipsilateral responses to magnetic stimulation. *Neuroreport*. 1996;7:1756–1760.
- Baker SN, Olivier E, Lemon RN. Coherent oscillations in monkey motor cortex and hand muscle EMG show task-dependent modulation. *J Physiol*. 1997;501:225–241.
- Conway BA, Halliday DM, Farmer SF, Shahani U, Maas P, Weir AI, Rosenberg JR. Synchronization between motor cortex and spinal motoneuronal pool during the performance of a maintained motor task in man. *J Physiol*. 1995;489:917–924.
- Mima T, Hallett M. Electroencephalographic analysis of corticomuscular coherence: reference effect, volume conduction and generator mechanism. *Clin Neurophysiol*. 1999;110:1892–1899.
- Salenius S, Portin K, Kajola M, Salmelin R, Hari R. Cortical control of human motoneuron firing during isometric contraction. *J Neurophysiol*. 1997;77:3401–3405.
- Mima T, Steger J, Schulman AE, Gerloff C, Hallett M. Electroencephalographic measurement of motor cortex control of motoneuronal firing in humans. *Clin Neurophysiol*. 2000;111:326–337.
- Oldfield RC. The assessment and analysis of handedness: the Edinburgh inventory. *Neuropsychologia*. 1971;9:97–113.
- Halliday DM, Rosenberg JR, Amjad AM, Breeze P, Conway BA, Farmer SF. A framework for the analysis of mixed time series/point process data: theory and application to the study of physiological tremor, single unit discharges and electromyogram. *Prog Biophys Mol Biol*. 1995;64:237–278.
- Mima T, Hallett M. Cortico-muscular coherence: a review. *J Clin Neurophysiol*. 1999;16:501–511.

16. Mima T, Simpkins N, Oluwatimilehin T, Hallett M. Force level modulates human cortical oscillatory activities. *Neurosci Lett*. 1999;275:77–80.
17. Brown P, Salenius S, Rothwell JC, Hari R. Cortical correlate of the Piper rhythm in humans. *J Neurophysiol*. 1998;80:2911–2917.
18. Mima T, Matsuoka T, Hallett M. Information flow from the sensorimotor cortex to muscle in humans. *Clin Neurophysiol*. 2001;112:122–126.
19. Palmer E, Ashby P, Hajek VE. Ipsilateral fast corticospinal pathways do not account for recovery in stroke. *Ann Neurol*. 1992;32:519–525.
20. Netz J, Lammers T, Hömberg V. Reorganization of motor output in the non-affected hemisphere after stroke. *Brain*. 1997;120:1579–1586.
21. Turton A, Wroe S, Trepte N, Fraser C, Lemon RN. Contralateral and ipsilateral EMG responses to transcranial magnetic stimulation during recovery of arm and hand function after stroke. *Electroencephalogr Clin Neurophysiol*. 1996;101:316–328.
22. Carr LJ, Harrison LM, Evans AL, Stephens JA. Patterns of central motor reorganization in hemiplegic cerebral palsy. *Brain*. 1993;116:1223–1247.
23. Weiller C, Chollet F, Friston KJ, Wise RJS, Frackowiak SJ. Functional reorganization of the brain in recovery from striatocapsular infarction in man. *Ann Neurol*. 1992;31:463–472.
24. Weder B, Knorr U, Herzog H, Nebeling B, Kleinschmidt A, Huang Y, Steinmetz H, Freund H-J, Seitz RJ. Tactile exploration of shape after subcortical ischaemic infarction studied with PET. *Brain*. 1994;117:593–605.
25. Seitz RJ, Huang Y, Knorr U, Tellmann L, Herzog H, Freund H-J. Large-scale plasticity of the human motor cortex. *Neuroreport*. 1995;6:742–744.
26. Ohara S, Nagamine T, Ikeda A, Kunieda T, Matsumoto R, Taki W, Hashimoto N, Baba K, Mihara T, Salenius S, Shibasaki H. Electrocorticogram-electromyogram coherence during isometric contraction of hand muscle in human. *Clin Neurophysiol*. 2000;111:2014–2024.
27. Turton A, Lemon RN. The contribution of fast corticospinal input to the voluntary activation of proximal muscles in normal subjects and in stroke patients. *Exp Brain Res*. 1999;129:559–572.